



PATIENT

Rufus Burns

SPECIES

Feline

BREED

Sphinx

SEX

Male Neutered

AGE

8 years

WEIGHT

9.5lbs

INTERPRETED BY

Maggie Machen
Lamy, DVM
DACVIM (Cardiology)

IMAGING PERFORMED BY

Pamela Harrigan,
RDMS

HOSPITAL NAME

Wignall Animal
Hospital

REFERRING VET

Dr. Cramb

INVOICE

25311

DATE

7/14/22

PRESENTING CLINICAL SIGNS

History: Recheck echo. History focal area of mild hypertrophy at base of septum - concern for mild HCM noted on prior echo 10/16/18 (Mandi Kleman, DVM, DACVIM-Cardiology). Currently, doing well with no clinical issues. Grade II/VI systolic murmur. BP: 162, 162, 164, 170mmHg.
-Pertinent previous echo findings: LA 1.27 cm; LA:Ao 1.19; IVS 0.43 cm; PW 0.45; laminar LVOT flow.

ECHOCARDIOGRAM FINDINGS

2D, m-mode, color flow and Doppler imaging is available.

Left ventricle: The LV diameter is normal with adequate myocardial function. The LV wall thicknesses are largely normal. There is a diffusely hyperechoic endocardium consistent with mild fibrosis. The endocardium appears mildly remodeled. The papillary muscles are mildly remodeled and hyperechoic.

Left atrium: The left atrium is normal in dimension. No obvious spontaneous contrast or thrombi seen.

Mitral valve: The mitral valve is normal in structure and mobility. No obvious systolic anterior motion is seen.

Aortic valve/aorta: The aortic valve is normal in morphology and mobility. Normal aortic outflow velocity; laminar flow. No aortic insufficiency.

Right ventricle: Normal right ventricular diameter and morphology indicating no overt evidence of pulmonary arterial hypertension.

Right atrium: The right atrium is normal in dimension.

Tricuspid valve: The tricuspid valve appears normal with no tricuspid regurgitation.

Pulmonic valve/pulmonary artery: The pulmonic valve is normal in morphology and mobility. No pulmonic insufficiency. Normal RVOT velocity; laminar flow.

Pericardium/other: No pericardial or pleural effusion noted. No obvious cardiac masses.

Heart rhythm: ECG reveals a sinus rhythm with an average HR of 200bpm.

2-Dimensional Measurements

Ao diam (cm)	1.1
LA diam (cm)	1.35
LA:Ao (Swe)	1.2
IVS thickness (cm)	0.51
LVID diastole (cm)	1.66
PW thickness (cm)	0.53
LVID systole (cm)	0.7
FS (%)	59

Doppler Measurements

PV Vmax (m/s)	1.1
AoV Vmax (m/s)	1.3
MR Vmax (m/s)	NA
TR Vmax (m/s)	NA
TR PG (mmHg)	NA

INTERPRETATION OF THE FINDINGS

Essentially normal cardiac structure and function. Previously noted basilar septal hypertrophy is not readily appreciated. The LV wall thickness is normal and there is no evidence of elevated left atrial pressure. There is mild remodeling and fibrosis of the left ventricular wall, which is considered normal. No cause for the murmur is identified in this study, making it likely physiologic in origin (i.e., secondary to tachycardia, volume changes, etc.).



PATIENT

Rufus Burns

SPECIES

Feline

BREED

Sphinx

SEX

Male Neutered

AGE

8 years

WEIGHT

9.5lbs

INTERPRETED BY

Maggie Machen
 Lamy, DVM
 DACVIM (Cardiology)

IMAGING

PERFORMED BY

Pamela Harrigan,
 RDCS

HOSPITAL NAME

Wignall Animal
 Hospital

REFERRING VET

Dr. Cramb

INVOICE

25311

DATE

7/14/22

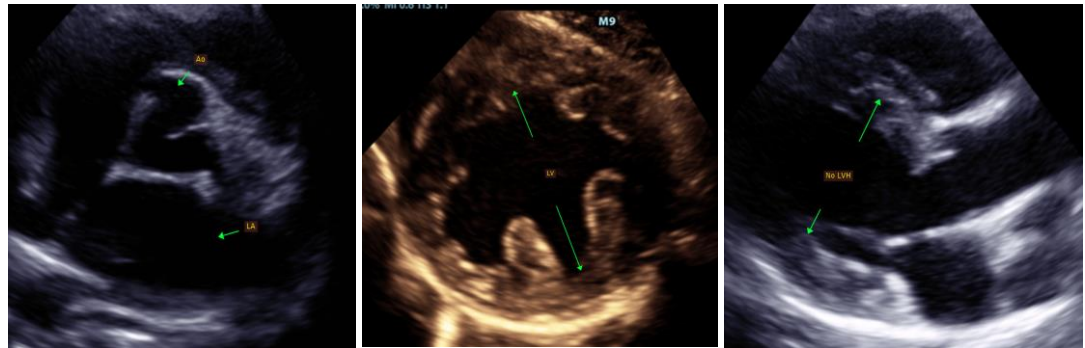
RECOMMENDATIONS

- Given these findings, no medications are indicated.
- No cardiac contraindication for general anesthesia. Mild IV fluid restriction is advised.
- Risk for complication with steroid use typically follows LA dilation, which in this case is low. That being said, any cat can experience unexpected signs of intolerance and monitoring of RR/RE is advised particularly in the initiation phase.
- Monitor for any clinical evidence of cardiac compromise, including respiratory changes and/or signs of a blood clot event (paralysis, neurologic changes, etc.).

PLAN

- Recommend recheck echocardiogram in 1 year to reassess murmur origin and screen for development of disease the pre-existing murmur may mask.

IMAGES



The information and recommendations provided are based on the images presented by the referring veterinarian. No evaluation can be communicated regarding pathology that was not visible in the image/video clips provided.

Thank you for this referral. This report was generated using transcription software, and minor dictation errors may be present. If the clinical or image interpretation does not parallel your findings or if I can be of any further assistance, please contact me.

Maggie Machen Lamy, DVM
 Diplomate of the American College of Veterinary Internal Medicine (Cardiology)
 info@sonopath.com